

**PATIENT**

Gillie Prevas

SPECIES

Canine

BREED

Miniature Aussie

SEX

Male Neutered

AGE

6.20.08

WEIGHT

22.2lbs

INTERPRETED BYMaggie Machen Lamy,
DVM, DACVIM
(Cardiology)**HOSPITAL NAME**White Marsh Animal
Hospital**REFERRING VET**

Dr. Brennan

INVOICE

29442

DATE

3.7.23

PRESENTING CLINICAL SIGNS

History: Grade 3/6 heart murmur. Bloated abdomen.

-Current medications: Lasix 12.5mg BID.

-Sedation used: Not required to complete full diagnostic ultrasound.

-Pertinent previous ultrasound results: No previous.

-STAT: Declined.

-Imaging performed by: Andi Parkinson, BS, RDMS.

ECHOCARDIOGRAM FINDINGS

2D, m-mode, color flow and doppler imaging is available. The mitral valve is diffusely thickened with prolapse into the left atrial lumen. A ruptured chordae tendineae is visualized. There is severe eccentric mitral regurgitation present. The MR velocity is normal. There is severe left atrial enlargement. There is mild left ventricular dilation. Left ventricular systolic function is hyperdynamic. There is normal systolic flow velocity across the aortic valve. The aortic valve appears trileaflet with normal mobility. The main pulmonary artery is mildly dilated. Moderate right atrial and ventricular dilation. The tricuspid valve is thickened with septal prolapse and moderate tricuspid regurgitation. Velocity is consistent with severe pulmonary hypertension. Mild pulmonic insufficiency; no aortic insufficiency. No pericardial effusion. No pleural effusion or cardiac masses are seen. Ascites seen on subcostal views.

CARDIAC CHART

CANINE CARDIAC PARAMETERS	MR VMAX (m/s)	TR VMAX (m/s)	LA/AO (Boon method)	LA/AO (Heart Base; Swe)	FS (%)	EF (%)	EPSS (cm)
NORMAL PARAMETER	4.5-5.5	<2.7	1.3	<1.6	28-40	40-100	<0.6
PATIENT	5.2	4.5	NM	2.0	57	88	NM
CANINE CARDIAC PARAMETERS	HR (BPM)	AV VMAX (m/s)	PV MAX (m/s)	BODY WEIGHT (kg)	LA 2D short axis Base view (cm)	LVIDd Avg; 2D and m-mode short axis (cm)	LVIDs Avg; 2D and m-mode short axis (cm)
NORMAL PARAMETER	50-100	0.7-1.7	0.7-1.6	BELOW	BELOW	BELOW	BELOW
PATIENT	126	1.3	NM	10.1	2.7	3.9	1.6
*Normal chamber parameters expressed as a mean value (SD)				3	1.27 (5.3)	2.46 (2.46)	1.36 (5.5)
BODY WEIGHT DEPENDENT PARAMETERS				5	1.40 (4.5)	2.74 (5.2)	1.60 (4.7)
*Note: All measurements based upon multi-modal images and methods. An average value is reported.				10	1.50 (3.8)	3.27 (3.5)	2.06 (3.1)
				15	1.83 (2.0)	3.71 (2.4)	2.43 (2.1)
				20	2.02 (1.9)	4.14 (2.2)	2.80 (2.0)
				25	2.18 (2.4)	4.48 (2.9)	3.10 (2.5)
				30	2.33 (3.3)	4.83 (3.9)	3.39 (3.4)
				35	2.48 (4.3)	5.17 (5.0)	3.69 (4.5)
				40	2.62 (5.2)	5.48 (6.1)	3.96 (5.4)
				50	2.88 (7.1)	6.07 (8.3)	4.46 (7.4)

Adapted from June Boon, Veterinary Echocardiography, 1998
Rishniw M and Hollis NE, J Vet Intern Med 2000; 14:429-435
Hansson et al, Vet Rad and Ultrasound 2002
Bonagura et al. Echocardiography: principles of interpretation, Vet Clin North Am 15:1177, 1995

INTERPRETATION OF THE FINDINGS & FURTHER RECOMMENDATIONS

Chronic degenerative valve disease causing severe mitral and moderate tricuspid regurgitation is identified. Severe four chamber dilation indicates the risk for spontaneous left or right-sided congestive heart failure is elevated. A ruptured chord is visualized, which is likely a chronic finding, given a lack of acute collapse or decompensation. Additionally, there is severe pulmonary hypertension present, which warrants additional therapy. This is in addition to full cardiac support, including diuretics as below.

These findings confirm ascites is cardiogenic in origin, consistent with right-sided CHF. Prognosis is guarded to poor long-term; however, most animals are able to maintain a good quality of life for some time. Patient will always be at risk for acute decompensation and/or sudden death.

Omega fatty acid supplementation and mild salt restriction may also be of some long-term benefit. Monitor for development of a worsening cough, labored breathing, exercise intolerance or worsening collapse episodes. Monitoring of sleeping breathing rates is recommended as the best way to screen for progression to CHF at home. Unfortunately, there is high risk for spontaneous CHF, worsening cough and/or malignant arrhythmias and sudden death in the future. The prognosis with this degree of disease is poor, with most dogs able to maintain a good QOL on medications for an average of 8-12 months.

Elective anesthesia is not advised.

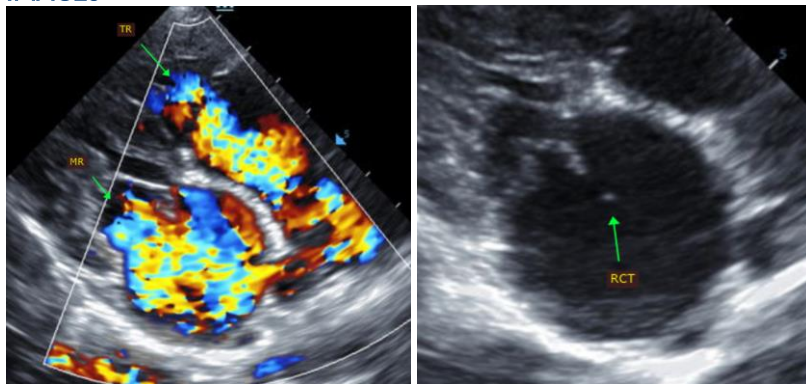
PLAN

Initiate spironolactone 1-2mg/kg PO q12h. Institute Sildenafil 1-2mg/kg PO 8h. Administer Lasix 1-2mg/kg PO q12h. Institute Pimobendan 0.3mg/kg PO q12h.

Recheck renal values and BP in 1-2 weeks, then every 3-4 months on diuretic therapy. If BP is >130mmHg and patient is doing well at home, institute ACEI 0.5mg/kg PO q12h (if hypotensive do not utilize).

A recheck echocardiogram is recommended in 4-6 months to screen for progression, sooner if clinical signs arise.

IMAGES



The information and recommendations provided are based on the images presented by the referring veterinarian. No evaluation can be communicated regarding pathology that was not visible in the image/video clips provided.

Thank you for this referral. This report was generated using transcription software, and minor dictation errors may be present. If the clinical or image interpretation does not parallel your findings or if I can be of any further assistance please contact me.

Maggie Machen Lamy, DVM
Diplomate of the American College of Veterinary Internal Medicine (Cardiology)
info@sonopath.com